

Accurate Assessment of Tibiofibular Alignment and Mental Workload are Improved by Inclusion of a Visual Aid on Center-Center X-rays

Christopher W. Reb DO², Chloe Baratta BS¹,
Jose Zermeno BS¹, and Jennifer A. Nichols PhD¹

¹University of Florida, Gainesville, FL ²Pennsylvania State University, Hershey, PA

Introduction: Malreduction is a widely recognized concern in ankle syndesmosis repair. A critical skill in assessing malreduction is the ability to accurately interpret intraoperative images. Yet, prior research indicates that experienced trauma-trained orthopaedic surgeons find identifying subtle fibular displacements on lateral ankle x-rays challenging, even when provided with a contralateral true lateral image for comparison [1]. Image interpretation errors may also be problematic when identifying a drill target for fixation. For example, the center-center technique [2] is a validated method for targeting trans-syndesmotic fixation through the geometric centers of the tibia and fibula [3,4]. However, it requires accurately interpreting intraoperative fluoroscopic images to identify a drill target that passes through the aligned centers of the tibia and fibula on an internally rotated lateral ankle x-ray view. In this context, the objective of this study was to evaluate whether surgical experience and/or inclusion of a visual aid improved surgeon accuracy in assessing center-center images.

Methods: Twenty-nine volunteers participated in this IRB-approved study. There were 12 attending orthopaedic surgeons (median PGY 13, range 7 to 37 years), 8 orthopaedic surgical residents (median PGY 3, range 3 to 5 years), and 9 medical students (median program year 2, range 2 to 4 years). All were blinded to the purpose of the study and their results. Each participant evaluated 90 lateral ankle images arranged in two sets (n = 45 images per set). The image sets were identical, except one set contained an additional visual aid, or crosshair, marking the center of the tibia. In each set, the fibula was displaced from -40% (posterior) to +40% (anterior) in increments of 10% from perfectly centered; each displacement and perfectly centered was represented 5 times in each set. Participants were asked to classify each image as “centered” (0% displacement) or “non-centered” (non-zero values of displacement) at the tibia height marked by a yellow horizontal line. Image and set order were randomized to control for learning effects. After each image set, participants completed the NASA Task Load Index, a self-reported metric of mental workload. Statistical analyses tested the hypotheses that surgical experience and the visual aid improved image interpretation accuracy and decreased mental workload. Effect of visual aid was assessed with one-tailed paired t-test comparing mean paired image change scores to 0 (i.e., null hypothesis of no change due to visual aid). Effect of clinical experience was assessed with ANOVA. Cumulative significance was $p \leq 0.05$ with the Bonferroni correction used for multiple comparisons.

Results: All participants accurately interpreted images that were perfectly centered or which illustrated large (>20%) fibular displacement. Yet, all participants were poor at identifying 10% fibula displacement in the anterior or posterior directions (Fig. 1). Performance, including at the level of 10% fibular displacement, was not significantly affected by clinical experience (Fig. 2). However, there was a significant improvement in accuracy when interpreting images that included the visual aid (Fig. 1 & 2). The positive impact of the visual aid ($p = 0.004$) was particularly evident for the challenging to interpret images (i.e., +/-10% fibular displacement, Fig. 2). The presence of the visual aid also significantly improved self-reported mental workload (Fig. 3). Notably, across all clinical experience levels when the visual aid was present, self-reported mental effort, perceived workload, and level of frustration decreased, while perceived rating of success increased (all $p < 0.004$). Workload was not significantly affected by clinical experience.

Conclusion: This study corroborates prior work [1] demonstrating that experienced orthopaedic surgeons find assessing small magnitudes of fibular displacement relative to the tibia on lateral ankle x-rays challenging. However, there were several important novel findings. First,

experienced orthopaedic surgeons' accuracy for identifying 10% fibula displacement from centered approximated that predicted by chance alone. Second, performance and mental load were not impacted by clinical experience when compared to orthopaedic residents and medical students. Third, the inclusion of a simple visual aid, such as a crosshair, improved image interpretation accuracy and decreased self-reported mental workload. Thus, this study provides foundational evidence that augmenting intraoperative imaging can improve visual processing ability at all levels of clinical experience. Future work should further validate these findings and characterize their connections to clinical and educational outcomes.

References: [1] Koenig et al. (2015) J Orthop Trauma, 29(9): 326-330. [2] Cancienne & Yarboro (2015) Tech Foot Ankle Surg, 14(3): 134-138. [3] Haupt et al. (2020) Foot Ankle Int., 41(9):1143-48. [4] Kennedy et al. (2014) The Foot, 24:157-60.

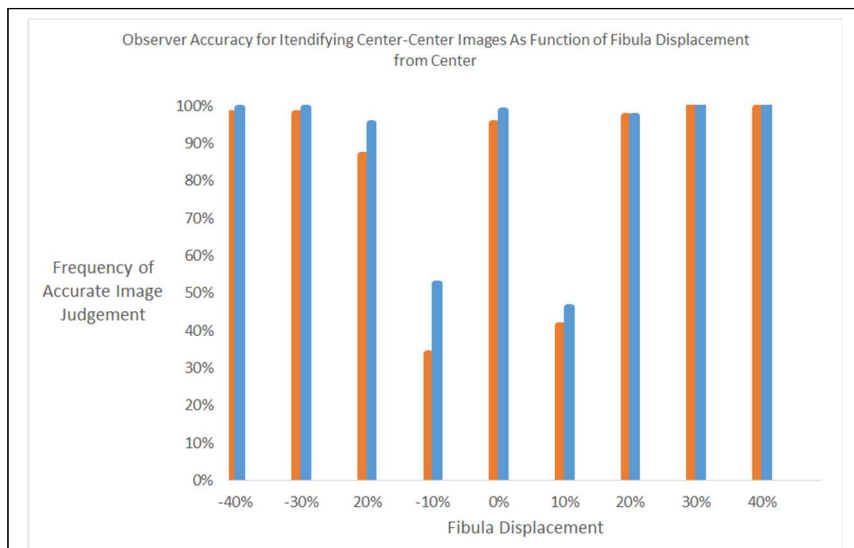


Figure 1. Percentage of accurately interpreted images versus depicted fibular displacement across all experience levels for images without (orange) and with (blue) the visual aid.

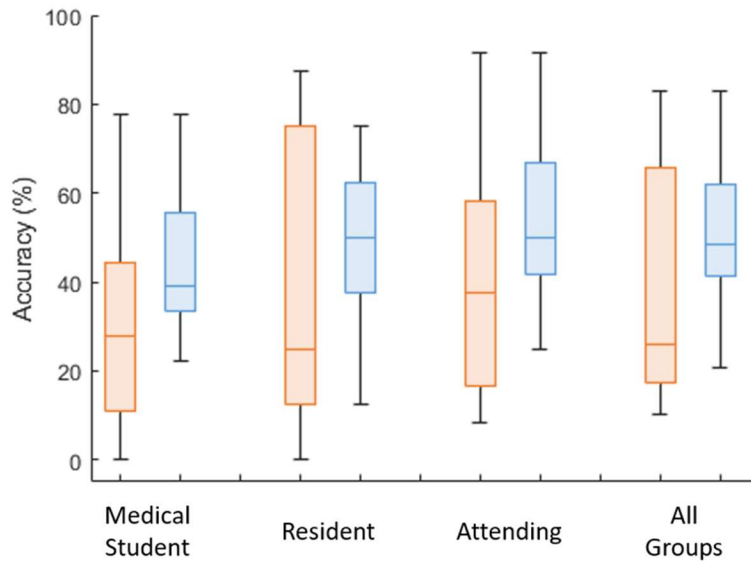


Figure 2. Percent of accurately interpreted images with +/-10% fibula displacement for each experience level and across all experience levels. Boxplots illustrate medians and interquartile ranges. Colors represent without (orange) and with (blue) the visual aid.

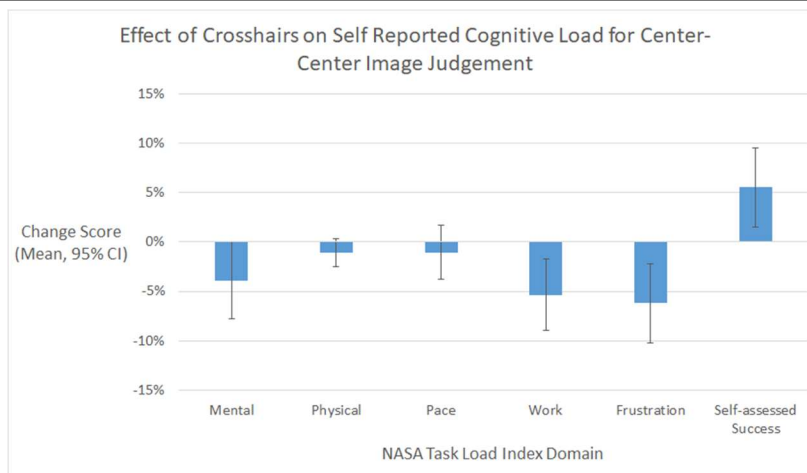


Figure 3. Mean difference in self-reported mental workload between image sets with and without the visual aid across all experience levels. Positive and negative values respectively indicate increased and decreased workload with presence of visual aid. Error bars are 95% CI.