A 3D Image-Based Comparison of the Center-Center and Transyndesmotic Axis Methods for Patient-Specific Fixation of the Ankle Syndesmosis

Nicholas J. Jackson[1], Christopher W. Reb DO[2], Joel B. Harley PhD[1], Jennifer A. Nichols PhD[1]
[1]University of Florida, Gainesville, FL [2]Pennsylvania State University, Hershey, PA
nicholas.jackson@ufl.edu

Disclosures: Nicholas J. Jackson (N), Christopher W. Reb (N), Joel B. Harley (N), Jennifer A. Nichols (N)

INTRODUCTION: Ankle syndesmosis fixation is indicated to remedy catastrophic injury to the ligaments adjoining the tibia and fibula. Iatrogenic syndesmotic malreduction (i.e., misalignment of the tibia and fibula) occurs often, with reported rates as high as 39% to 54% [1, 2]. The fixation axis (or drill path for implant placement) is a surgeon-controlled factor influencing the accuracy of syndesmosis alignment [3]. Despite efforts to identify a surgical technique for locating the fixation axis and reducing the rate of malreduction, no patient-specific technique has gained widespread adoption. One barrier to adoption is limited validation of the proposed techniques relative to a gold standard. The centroid axis has been described as the *ideal*, patient-specific fixation axis and is drawn through the geometric centers (centroids) of the tibia and fibula; however, this axis cannot be directly visualized during surgery [4]. The center-center method, which is an implementable surgical technique, can localize the centroid axis [5]. Another surgical technique, known as the transyndesmotic axis (TSA), appears to achieve anatomic alignment [3, 6], but the TSA has not been directly evaluated in relation to the centroid axis. Thus, the objective of this study was to evaluate whether the center-center and centroid axes, which closely align, are equivalent to the TSA.

METHODS: Computed tomography (CT) scans (0.5 mm slice thickness, 512 x 512 resolution, 135 kVp, and 80mA) of six through-knee cadaveric lower limb specimens were used to digitally reconstruct the tibia and fibula. Limb orientation was standardized across specimens according to an anatomic coordinate system aligned to a true lateral view of the distal tibia's articular surface [6]. For each specimen, the TSA, center-center axis, and centroid axis were calculated. The TSA was calculated as the perpendicular bisector to the line tangent to the two peaks of the tibial incisura on axial slices (Fig. 1A, green). This was calculated for every axial slice where the incisura was present. The angle between the TSA and the true lateral view was measured as a function of tibia height. For comparison, the center-center and centroid axes were also calculated as functions of tibia height. The center-center axis was calculated using digitally reconstructed radiographs [7], which simulate fluoroscopic images to identify the locations at which the fibula is centered within the tibia (Fig. 1B, arrow). The centroid axis was identified by fitting polygons to the edges of the tibia and fibula on axial CT slices, then calculating the geometric centroids and projecting a vector through them (Fig. 1A, blue). Descriptive statistics (means and 95% confidence intervals) of the three axes were calculated and compared.

RESULTS: The center-center axis and TSA differed by a mean of 5.1 degrees with 95% CI of 3.1 degrees (Fig. 2, orange) while the centroid axis and TSA differed by a mean of 4.3 degrees with 95% CI of 2.5 degrees (Fig. 2, blue). The center-center and centroid axes were consistently aligned with less than a 1-degree difference along the length of the tibia (Fig. 3, blue compared to orange). In contrast, the TSA and centroid axis were not consistently aligned (Fig. 3, blue compared to green). In fact, the mean TSA was outside the 95% CI of the centroid axis for the majority of heights below 10 mm (Fig. 3). Despite these differences, all three axes demonstrated the same trend relative to true lateral; in other words, as the distance from the ankle joint increases the magnitude of internal rotation from true lateral (i.e., the limb rotation needed to locate each axis) also increases (Fig. 3). Importantly, the TSA is not identifiable above the tibial incisura, which occurred at a mean of 14.4 mm (SD 6.9 mm) above the ankle joint (Fig. 2 & 3), whereas the center-center and centroid axes were identifiable along the entire length of the tibia (data not shown).

DISCUSSION: The center-center method consistently localized a patient-specific fixation axis that is very closely aligned with the centroid axis; this finding supports and expands upon previous work comparing these axes [5]. While the TSA shows some overlap with the locations of the center-center and centroid axes, the TSA does not consistently localize with these axes; thus, TSA cannot be considered equivalent to either the center-center or centroid axes. Immediate future research will evaluate whether incisura depth is associated with the range of heights at which the TSA is viable. We also plan to evaluate the sensitivity of the TSA by selecting points for the tibial incisura that vary slightly from each other and comparing how these minor perturbations change the alignment of the identified drill path. In the long-term, studies evaluating differences in clinical outcomes between each syndesmosis fixation technique are needed.

SIGNIFICANCE/CLINICAL RELEVANCE: Confirmation that the center-center and centroid axes are not equivalent to the TSA provides the groundwork for future research into the advantages and disadvantages of these methods, thereby enabling study of both their practicality and impact on clinical outcomes.

REFERENCES: [1] Sagi et al. (2012) *J Orthop Trauma*, 26(7): 439-43. [2] Gardner et al. (2006) *Foot Ankle Int*, 27(10): 788-92. [3] Cosgrove et al. (2018) *J Orthop Trauma*, 31(8): 440-6. [4] Kennedy et al. (2014) *The Foot*, 24:157-60. [5] Haupt et al. (2020) *Foot Ankle Int*, 41(9):1143–8. [6] Putnam et al. (2017) *Injury*, 48(3): 770-5. [7] Sherouse et al. (1990) *Int J Radiat Oncol Biol Phys*, 18(3): 651-8.

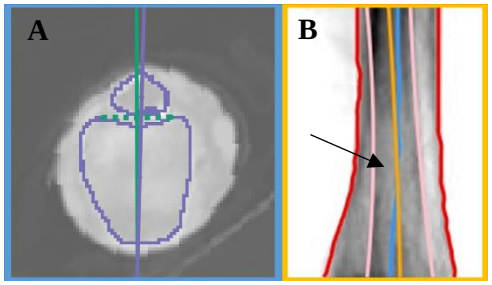

Figure 1: (a) For a given axial slice, the centroid axis is defined as the vector through the centroids of the tibia and fibula (blue). The TSA is defined as the perpendicular bisector (green, solid) to the vector between the crests of the tibial incisura (green, dotted). **(b)** At a given height, the center-center axis is defined as the vector perpendicular to the point at which the midlines of the fibula and tibia cross (arrow).

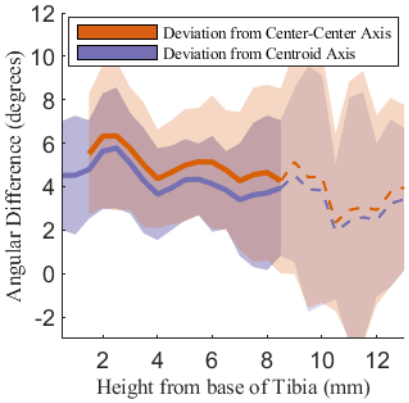

Figure 2: Angular difference between the TSA and the center-center (orange) and centroid (blue) axes from 0 to 13 mm above the tibial plafond. Shading represents 95% CI. Dashed line represents the range of heights for which more than half, but not all limbs have an identifiable TSA.

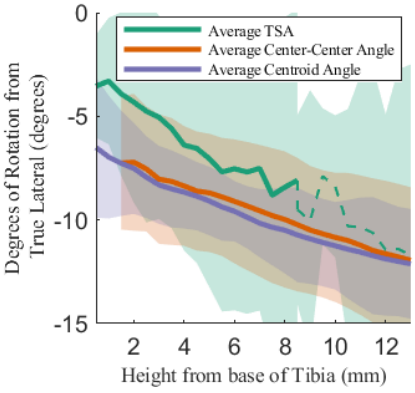

Figure 3: Limb rotation from true lateral required to achieve alignment with the TSA, center-center axis, and centroid axis. Negative angles indicate internal rotation. Shading represents 95% CI. Dashed line represents the range of heights for which more than half, but not all limbs have an identifiable TSA.